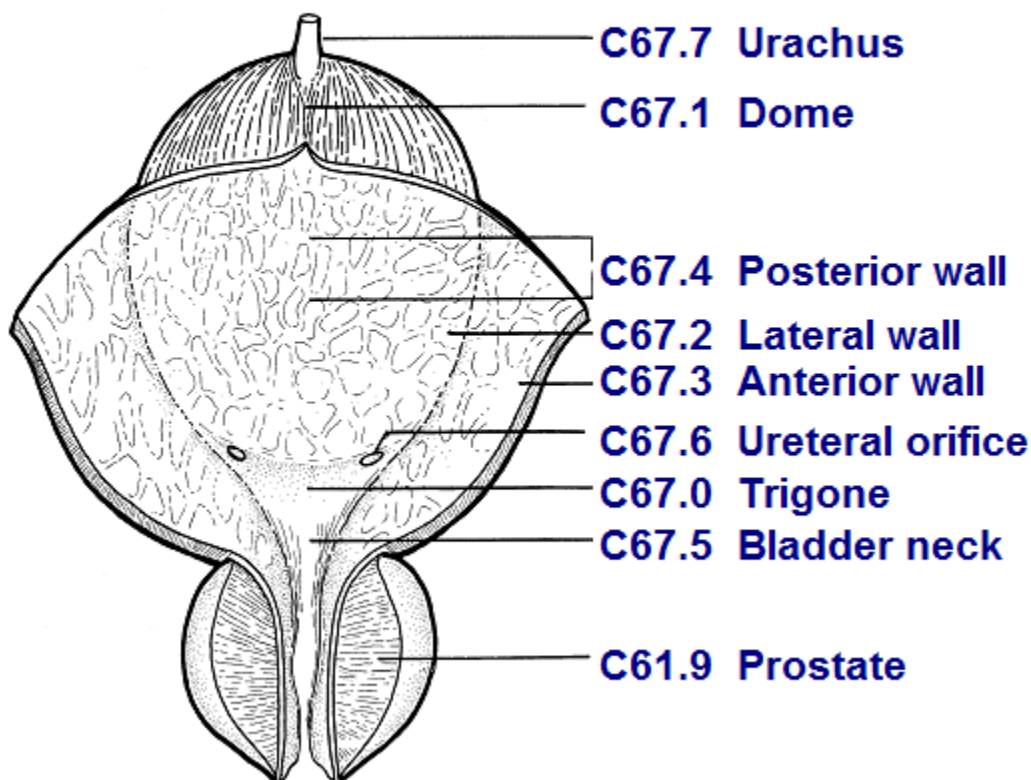


Coding Guidelines
BLADDER
C670–C679

Primary Site

- C670 Trigone of bladder
Base of bladder
Floor
Below interureteric ridge (interureteric crest, or interureteric fold)
- C671 Dome of bladder
Vertex
Roof
Vault
- C672 Lateral wall of bladder
Right wall
Left wall
Lateral to ureteral orifice
Sidewall
- C673 Anterior wall of bladder
- C674 Posterior wall of bladder
- C675 Bladder neck
Vesical neck
Internal urethral orifice
Internal urethral/uretero orifice
- C676 Ureteric orifice
Just above ureteric orifice
- C677 Urachus
Mid umbilical ligament
Urachal remnant
- C678 Overlapping lesion of bladder
Lateral-posterior wall (hyphen)
Fundus
- C679 Bladder, NOS
Lateral posterior wall (no hyphen)

Bladder Anatomy and ICD-O-3



Source: TNM Atlas, 3rd edition, 2nd revision

Priority Order for Coding Subsites

Use the information from reports in the following priority order to code a subsite when the medical record contains conflicting information:

Operative report (TURB)
Pathology report

Multifocal Tumors

Invasive tumor in more than one subsite

Assign site code C679 when the tumor is multifocal (separate tumors in more than one subsite of the bladder).

If the TURB or pathology proves invasive tumor in one subsite and in situ tumor in all other involved subsites, code to the subsite involved with **invasive** tumor.

Bladder Wall Pathology

The bladder wall is composed of three layers. There may be “sub layers” within the major layer of the bladder.

Bladder Layer	Sub layer	Synonyms	Staging	Description
Mucosa		Epithelium, transitional epithelium, urothelium, mucosal surface, transitional mucosa	No blood vessels, in situ/noninvasive	First layer on inside of bladder; Lines bladder, ureters, and urethra
	Basement membrane		No invasion of basement membrane is in situ Invasion/penetration of basement membrane is invasive	Single layer of cells that lies beneath the mucosal layer separating the epithelial layer from the lamina propria
	Submucosa	Submucous coat, lamina propria, areolar connective tissue	Invasive	Areolar connective tissue interlaced with the muscular coat. Contains blood vessels, nerves, and in some regions, glands
Lamina propria		Submucosa, Suburothelial connective tissue, subepithelial tissue, stroma, muscularis mucosa, transitional epithelium	Invasive	
Muscle	Bladder wall	Muscularis, muscularis propria, muscularis externa, smooth muscle	Invasive	

Tumor extends through the bladder wall (invades regional tissue) when the tumor is stated to involve one of the following areas:

Serosa (Tunica serosa): The outermost serous coat is a reflection of the peritoneum that covers the superior surface and the upper parts of the lateral surfaces of the urinary bladder. The serosa is part of visceral peritoneum. The serosa is reflected from these bladder surfaces onto the abdominal and pelvic walls.

Perivesical fat

Adventitia: Some areas of the bladder do not have a serosa. Where there is no serosa, the connective tissue of surrounding structures merges with the connective tissue of the bladder and is called adventitia.

HISTOLOGY¹

Most bladder cancers are transitional cell carcinomas. Other types include squamous cell carcinoma and adenocarcinoma.

Adenocarcinomas tend to occur in the urachus or, frequently, the trigone of the bladder²

Other bladder histologic types include sarcoma, lymphoma, and small cell carcinoma.

Rhabdomyosarcoma occurs in children.

Behavior Code

Code the behavior as malignant /3, **not** in situ /2, when

- the only surgery performed is a transurethral resection of the bladder (TURB) documenting that depth of invasion cannot be measured because there is no muscle in the specimen
- and**
- the physician's TNM designation is **not** available
- or**
- the pathology report says the submucosa is invaded with tumor
- or**
- the pathology report does not mention whether the submucosa is free of tumor or has been invaded by tumor

Code the behavior as in situ /2 when

- the TNM designation is Ta for TURB with no muscle in the specimen
- or**
- the pathology report says the submucosa is free of tumor

FIRST COURSE TREATMENT

TREATMENT MODALITIES (most common treatments)

TURB with fulguration

TURB with fulguration followed by intravesical BCG (bacillus Calmette-Guerin) is usually used for patients with multiple tumors or for high-risk patients.

TURB with fulguration followed by intravesical chemotherapy

Photodynamic therapy (PDT) using laser light and chemotherapy

Segmental cystectomy (rare)

Radical cystectomy in patients with extensive or refractory superficial tumor

Internal irradiation (needles, seeds, wires, or catheters placed into or near the tumor) with or without external-beam irradiation

Chemotherapy

Immunotherapy/biologic therapy

¹ PDQ

² Clinical Oncology, 8th edition