

## Coding Guidelines

### Bladder C670–C679

#### Reportability

Do **not** report bladder cancer based on **UroVysion** test results alone. Report the case if there is a physician statement of malignancy and/or the patient was treated for cancer.

#### Not reportable

Papillary urothelial neoplasms of low malignant potential (PUNLMs)

The WHO classification categorizes "PUNLMP" as borderline, 8130/1. The definition is "a papillary urothelial tumor which resembles the exophytic urothelial papilloma, but shows increased cellular proliferation exceeding the thickness of normal urothelium." The histopathologic description is "the papillae of PUNLMP are discrete, slender and not fused and are lined by multilayered urothelium with minimal to absent cytologic atypia....Mitoses are rare and have a basal location."

Papilloma of bladder

The WHO classification categorizes "urothelial papilloma" as benign, 8120/0. The definition is "composed of a delicate fibrovascular core covered by urothelium indistinguishable from that of normal urothelium." The histopathologic description is "characterized by discrete papillary fronds with occasional branching...the epithelium lacks atypia...mitoses are absent to rare and, if present, are basal in location and not abnormal. The lesions are often small and occasionally show concomitant inverted growth pattern. Rarely, papilloma may show extensive involvement of the mucosa."

#### Primary Site

C670 Trigone of bladder

Base of bladder

Floor

Below interureteric ridge\* (interureteric crest, or interureteric fold)

C671 Dome of bladder

Vertex

Roof

Vault

C672 Lateral wall of bladder

Right wall

Left wall

Lateral to ureteral orifice

Sidewall

C673 Anterior wall of bladder

C674 Posterior wall of bladder

C675 Bladder neck  
 Vesical neck  
 Internal urethral orifice  
 Internal urethral/uretero orifice

C676 Ureteric orifice  
 Just above ureteric orifice

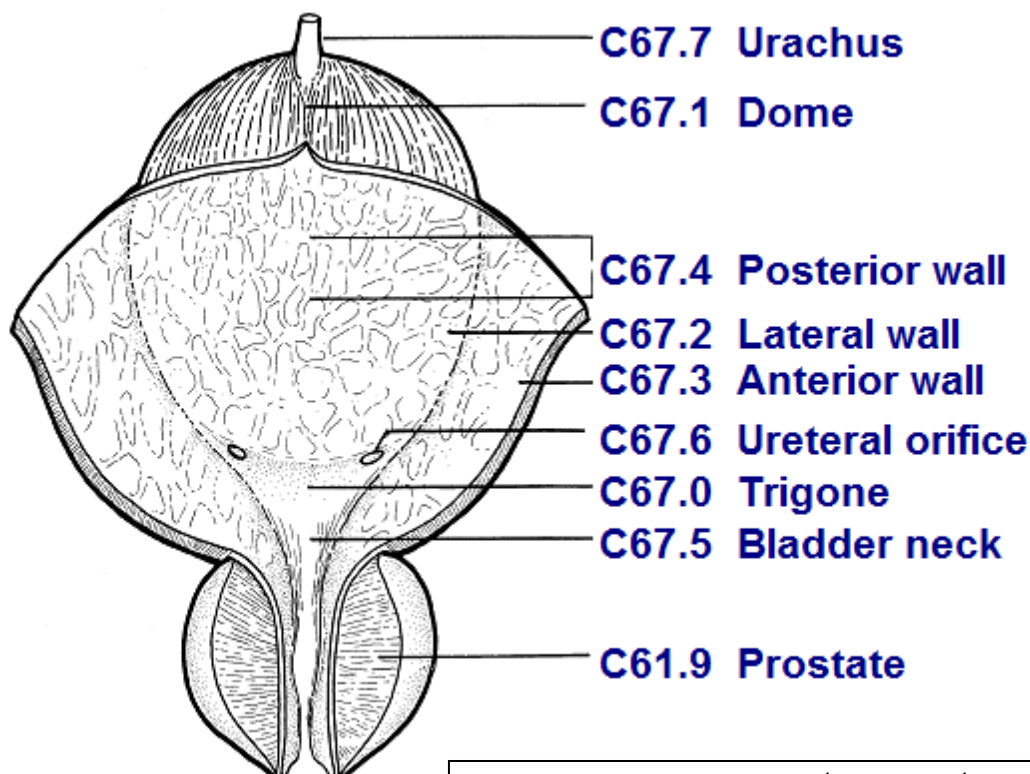
C677 Urachus  
 Mid umbilical ligament  
 Urachal remnant

C678 Overlapping lesion of bladder  
 Lateral-posterior wall (hyphen)  
 Fundus

C679 Bladder, NOS  
 Lateral posterior wall (no hyphen)

\*The **interureteric ridge** is a fold of mucous membrane extending across the bladder between the ureteric orifices and forms one of the boundaries for the trigone of the bladder.

**Bladder Anatomy and ICD-O-3**



Source: UICC TNM Atlas, 3<sup>rd</sup> edition, 2<sup>nd</sup> revision

### Priority Order for Coding Subsites

Use the information from reports in the following priority order to code a subsite when the medical record contains conflicting information:

Operative report (TURB)  
Pathology report

### Multifocal Tumors

Invasive tumor in more than one subsite

Assign site code C679 when the tumor is multifocal (separate tumors in more than one subsite of the bladder).

If the TURB or pathology proves invasive tumor in one subsite and in situ tumor in all other involved subsites, code to the subsite involved with **invasive** tumor.

## Bladder Wall Pathology

The bladder wall is composed of three layers. There may be “sub layers” within the major layer of the bladder.

Bladder Layer	Sub layer	Synonyms	Staging	Description
Mucosa		Epithelium, transitional epithelium, urothelium, mucosal surface, transitional mucosa	No blood vessels, in situ/noninvasive	First layer on inside of bladder; Lines bladder, ureters, and urethra
	Basement membrane		No invasion of basement membrane is in situ Invasion/penetration of basement membrane is invasive	Single layer of cells that lies beneath the mucosal layer separating the epithelial layer from the lamina propria
	Submucosa	Submucous coat, lamina propria, areolar connective tissue	Invasive	Areolar connective tissue interlaced with the muscular coat. Contains blood vessels, nerves, and in some regions, glands
Lamina propria		Submucosa, Suburothelial connective tissue, subepithelial tissue, stroma, muscularis mucosa, transitional epithelium	Invasive	
Muscle	Bladder wall	Muscularis, muscularis propria, muscularis externa, smooth muscle	Invasive	

Tumor extends through the bladder wall (invades regional tissue) when the tumor is stated to involve one of the following areas:

**Serosa (Tunica serosa):** The outermost serous coat is a reflection of the peritoneum that covers the superior surface and the upper parts of the lateral surfaces of the urinary bladder. The serosa is part of visceral peritoneum. The serosa is reflected from these bladder surfaces onto the abdominal and pelvic walls.

### Perivesical fat

**Adventitia:** Some areas of the bladder do not have a serosa. Where there is no serosa, the connective tissue of surrounding structures merges with the connective tissue of the bladder and is called adventitia.

## Histology<sup>1</sup>

Most bladder cancers are transitional cell carcinomas. Other types include squamous cell carcinoma and adenocarcinoma.

Adenocarcinomas tend to occur in the urachus or, frequently, the trigone of the bladder<sup>2</sup>

Other bladder histologic types include sarcoma, lymphoma, and small cell carcinoma.

Rhabdomyosarcoma occurs in children.

## Behavior Code

Code the behavior as malignant /3, **not** in situ /2, when

- the only surgery performed is a transurethral resection of the bladder (TURB) documenting that depth of invasion cannot be measured because there is no muscle in the specimen

**AND**

- the physician's TNM designation is **not** available

**OR**

- the pathology report says the submucosa is invaded with tumor

**OR**

- the pathology report does not mention whether the submucosa is free of tumor or has been invaded by tumor

Code the behavior as in situ /2 when

- the TNM designation is Ta for TURB with no muscle in the specimen

**OR**

- the pathology report says the submucosa is free of tumor

## First Course Treatment

BCG

Code BCG as both surgery and immunotherapy. See the SEER manual, appendix C, Bladder Surgery Codes, SEER Note under code 16

### *Treatment Modalities (most common treatments)*

TURB with fulguration

TURB with fulguration followed by intravesical BCG (bacillus Calmette-Guerin) is usually used for patients with multiple tumors or for high-risk patients.

TURB with fulguration followed by intravesical chemotherapy

Photodynamic therapy (PDT) using laser light and chemotherapy

Segmental cystectomy (rare)

---

<sup>1</sup> PDQ

<sup>2</sup> Clinical Oncology, 8th edition

Radical cystectomy in patients with extensive or refractory superficial tumor  
Internal irradiation (needles, seeds, wires, or catheters placed into or near the tumor) with or without  
external-beam irradiation  
Chemotherapy  
Immunotherapy/biologic therapy