

Coding Guidelines

Bladder C670–C679

Reportability

Do **not** report bladder cancer based on **UroVysion** test results alone. Report the case if there is a physician statement of malignancy and/or the patient was treated for cancer.

Not reportable

Papillary urothelial neoplasms of low malignant potential (PUNLMs)

The WHO classification categorizes "PUNLMP" as borderline, 8130/1. The definition is "a papillary urothelial tumor which resembles the exophytic urothelial papilloma, but shows increased cellular proliferation exceeding the thickness of normal urothelium." The histopathologic description is "the papillae of PUNLMP are discrete, slender and not fused and are lined by multilayered urothelium with minimal to absent cytologic atypia....Mitoses are rare and have a basal location."

Papilloma of bladder

The WHO classification categorizes "urothelial papilloma" as benign, 8120/0. The definition is "composed of a delicate fibrovascular core covered by urothelium indistinguishable from that of normal urothelium." The histopathologic description is "characterized by discrete papillary fronds with occasional branching...the epithelium lacks atypia...mitoses are absent to rare and, if present, are basal in location and not abnormal. The lesions are often small and occasionally show concomitant inverted growth pattern. Rarely, papilloma may show extensive involvement of the mucosa."

Primary Site

C670 Trigone of bladder

Base of bladder

Floor

Below interureteric ridge* (interureteric crest or interureteric fold)

C671 Dome of bladder

Vertex

Roof

Vault

C672 Lateral wall of bladder

Right wall

Left wall

Lateral to ureteral orifice

Sidewall

C673 Anterior wall of bladder

C674 Posterior wall of bladder

C675 Bladder neck
 Vesical neck
 Internal urethral orifice
 Internal urethral/uretero orifice

C676 Ureteric orifice
 Just above ureteric orifice

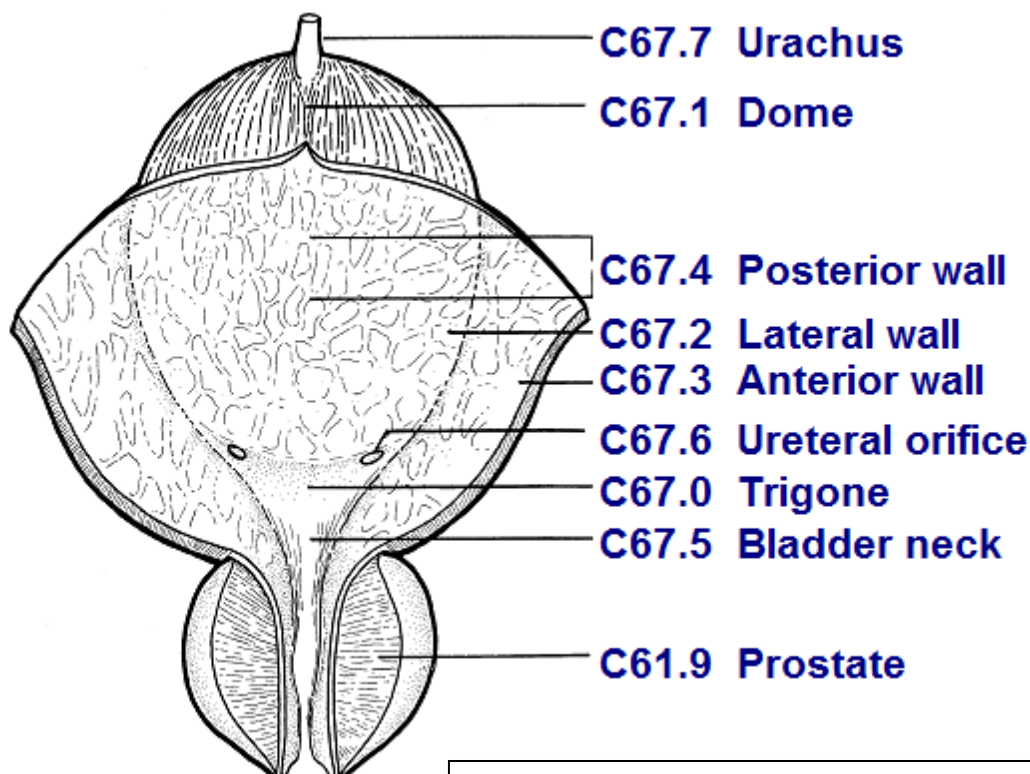
C677 Urachus
 Mid umbilical ligament
 Urachal remnant

C678 Overlapping lesion of bladder
 Lateral-posterior wall (hyphen)
 Fundus

C679 Bladder, NOS
 Lateral posterior wall (no hyphen)

* The **interureteric ridge** is a fold of mucous membrane extending across the bladder between the ureteric orifices and forms one of the boundaries for the trigone of the bladder.

Bladder Anatomy and ICD-O-3



Source: UICC TNM Atlas, 3rd edition, 2nd revision

Priority Order for Coding Subsites

Use the information from reports in the following priority order to code a subsite when the medical record contains conflicting information:

Operative report (TURB)
Pathology report

Multifocal Tumors

Assign site code C679 when there are multifocal tumors all of the same behavior in more than one subsite of the bladder and the specific subsite of origin is not known.

If the TURB or pathology proves invasive tumor in one subsite and in situ tumor in all other involved subsites, code to the subsite involved with **invasive** tumor.

Bladder Wall Pathology

The bladder wall is composed of three layers. There may be “sub layers” within the major layer of the bladder.

Bladder Layer	Sub Layer	Synonyms	Staging	Description
Mucosa		Epithelium, transitional epithelium, urothelium, mucosal surface, transitional mucosa	No blood vessels, in situ/noninvasive	First layer on inside of bladder; Lines bladder, ureters, and urethra
	Basement membrane		No invasion of basement membrane is in situ Invasion/penetration of basement membrane is invasive	Single layer of cells that lies beneath the mucosal layer separating the epithelial layer from the lamina propria
	Submucosa	Submucous coat, lamina propria, areolar connective tissue	Invasive	Areolar connective tissue interlaced with the muscular coat. Contains blood vessels, nerves, and in some regions, glands
Lamina propria		Submucosa, Suburothelial connective tissue, subepithelial tissue, stroma, muscularis mucosa, transitional epithelium	Invasive	
Muscle	Bladder wall	Muscularis, muscularis propria, muscularis externa, smooth muscle	Invasive	

Tumor extends through the bladder wall (invades regional tissue) when the tumor is stated to involve one of the following areas.

Serosa (Tunica serosa): The outermost serous coat is a reflection of the peritoneum that covers the superior surface and the upper parts of the lateral surfaces of the urinary bladder. The serosa is part of visceral peritoneum. The serosa is reflected from these bladder surfaces onto the abdominal and pelvic walls.

Perivesical fat

Adventitia: Some areas of the bladder do not have a serosa. Where there is no serosa, the connective tissue of surrounding structures merges with the connective tissue of the bladder and is called adventitia.

Histology¹

Over 90% of bladder cancers are urothelial (transitional) cell carcinomas, derived from the uroepithelium. Other types include squamous cell carcinoma (about 2% to 7%) and adenocarcinoma (about 2%). Adenocarcinomas may be of urachal origin or nonurachal origin, with the nonurachal type generally thought to arise from metaplasia of chronically irritated transitional epithelium. Small cell carcinoma, and rarely sarcoma, can also occur. Childhood rhabdomyosarcoma, a type of sarcoma, can form in muscle tissue of the bladder.

Behavior Code

Especially for bladder, the behavior code and the stage may not match. Different rules apply to assigning behavior code compared to assigning stage. Use the rules as they apply to each data item, do not mix instructions from one data item to another.

Code the behavior as **malignant** (/3), not in situ (/2), when

- The diagnosis is high grade urothelial carcinoma **AND** there is no information regarding invasion

OR

- The pathology report says the submucosa is invaded with tumor

OR

- The only surgery performed is a transurethral resection of the bladder (TURB) documenting that depth of invasion cannot be measured because there is no muscle in the specimen **AND**

- o There is no information regarding invasion and the physician's TNM designation is not available

OR

- o The pathology report does not mention whether the submucosa is free of tumor or has been invaded

Code the behavior as **in situ** (/2) when

- The diagnosis is low grade urothelial carcinoma **AND** there is no information regarding invasion

OR

- The pathology report says the submucosa is free of tumor

OR

¹ https://www.cancer.gov/types/bladder/hp/bladder-treatment-pdq#_33

- The only surgery performed is a transurethral resection of the bladder (TURB) documenting that depth of invasion cannot be measured because there is no muscle in the specimen **AND**
 - The TNM designation is Ta or Tis for TURB with no muscle in the specimen

OR

- The pathology report includes terminology using terms such as
 - Non-invasive
 - No stromal invasion identified
 - No invasion identified
 - No lamina propria invasion identified
 - Extent of invasion: Absent

First Course Treatment

BCG

Code BCG as both surgery and immunotherapy. See the SEER manual, Appendix C, Bladder Surgery Codes, SEER Note under code 16.

Treatment Modalities (most common treatments)

TURB with fulguration

TURB with fulguration followed by intravesical BCG (bacillus Calmette-Guerin) is usually used for patients with multiple tumors or for high-risk patients.

TURB with fulguration followed by intravesical chemotherapy

Photodynamic therapy (PDT) using laser light and chemotherapy

Segmental cystectomy (rare)

Radical cystectomy in patients with extensive or refractory superficial tumor

Internal irradiation (needles, seeds, wires, or catheters placed into or near the tumor) with or without external-beam irradiation

Chemotherapy

Immunotherapy/biologic therapy